

Surgical approaches to PITUITARY ADENOMAS



HISTORY OF PITUITARY SURGERY



- In 1893, Caton and Paul attempted to explore sella turcica via lateral sub temporal route along with orbital exenteration.
- The transfrontal approach was first used by Krause in 1905

HISTORY OF PITUITARY SURGERY



- The transsphenoidal approach was used by Kanavel via infranasal route and via endonasal route by Hirsch.
- Sublabial approach was adopted by Cushing in 1910.
- The transsphenoidal route was reevaluated by Guiot and popularized by Hardy and Wigser using image intensifier and operating microscope.

Surgical approaches

<u>Extra cranial</u>	<u>Trans cranial</u>
<u>A. Trans sphenoidal</u>	<u>A. Intra dural</u>
- sublabial trans sphenoidal	- sub frontal
- trans- nasal, trans- septal, trans- sphenoidal	- pterional
- trans maxillary trans ethmoido- sphenoidal	- orbito zygomatic
- fronto orbital external trans ethmoidal	- sub temporal
<u>B. Endoscopic endonasal</u>	<u>B. Extra dural:</u> Orbito zygomatic



The following three anatomic concepts that are fundamental to the safe execution of a transsphenoidal microsurgical procedure:

- 1. The pituitary gland is an extra-arachnoid structure.
- 2 The pituitary gland is strictly in the midline, with hazards to either side.
- 3. It is important to recognize the residual normal anterior pituitary, especially during operations to remove pituitary macro adenoma.



Transsphenoidal operation for the removal of a pituitary adenoma should be executed with respect for the preservation of the integrity of the arachnoid membrane, which acts as a protective shield between the surgical manipulation and the subarachnoid space, with its vital neurovascular structures. Thus, the surgical dissection should be performed along the tumor-arachnoid interface.

Trans nasal approaches



- **Indications:**

1. For most pituitary tumors
2. Craniopharyngiomas and other lesions which are primarily sellar
3. Rathke's cleft cyst
4. Apoplexy

- **Contraindications:**

1. Infection / sinusitis
2. Tumor having predominant supra/ para sellar invasion
3. Bare carotids
4. Conchal sella

Anatomical aspects



- Pituitary gland is housed in the sella
- Depth of 10 to 12 mm
- Width of 10- 15mm

Sphenoid Sinus

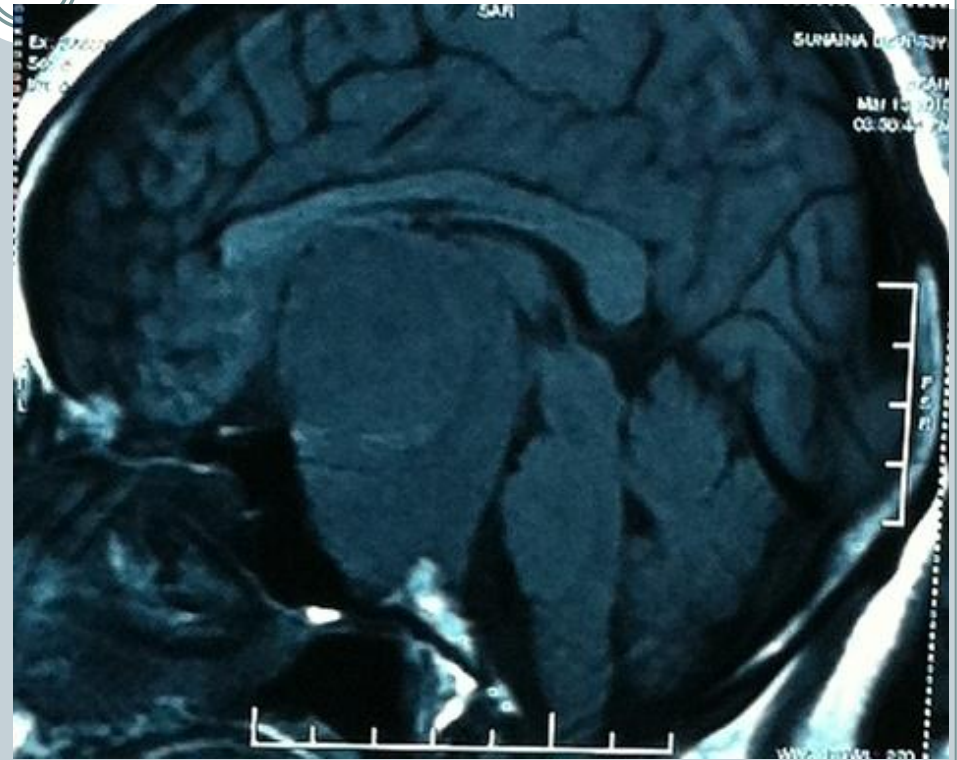
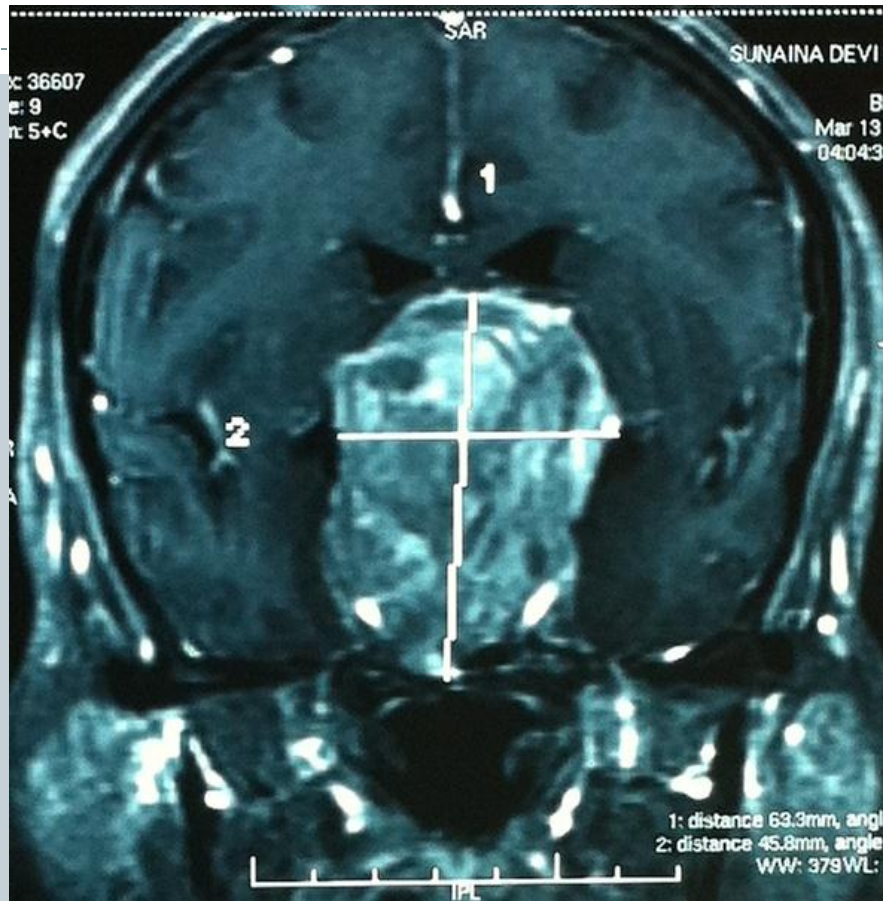


- Sphenoid sinus
- 46% of times septum away from midline
- Hamberger classification:
 - conchal
 - pre sellar
 - sellar
- Carotids bulge into supero lateral walls in 71%
- Separated by thin bone in 96%
- Inter carotid distance usually 10-12 mm

Preoperative evaluation



- X-Ray skull
- NCCT head with thin coronal cuts
- MRI brain
- Complete hormone evaluation
- Visual acuity and visual field charting
- Nasal swab



Positioning

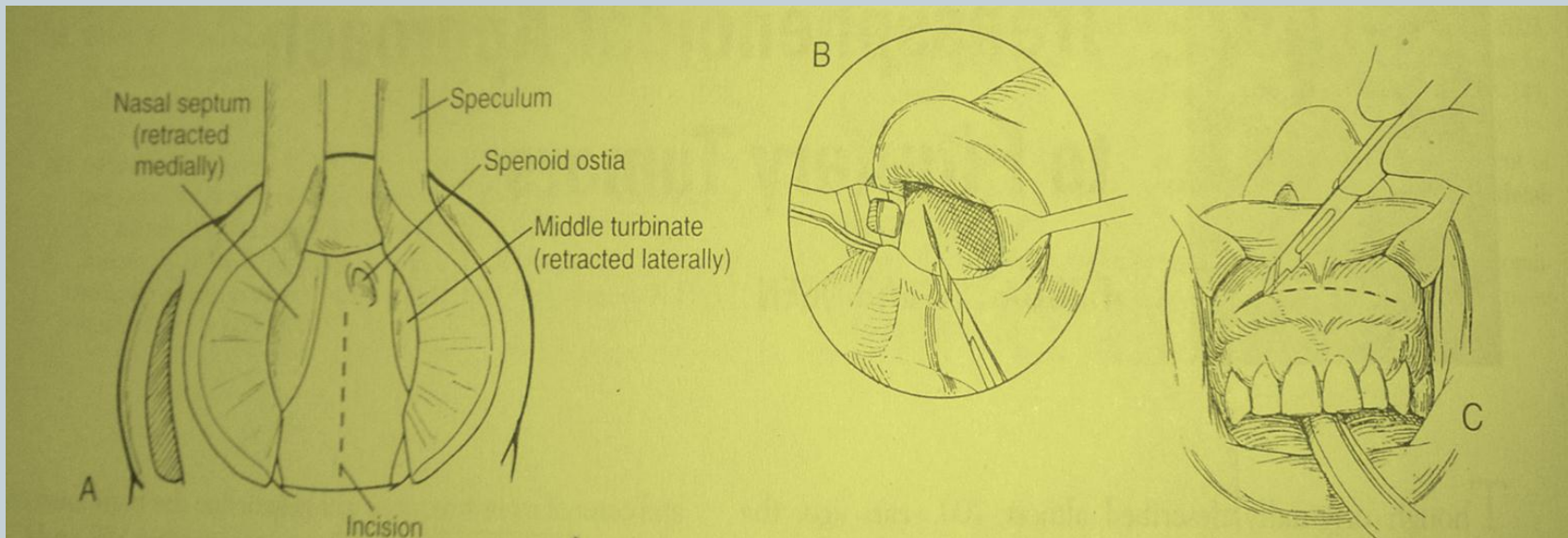


- Either horse shoe or plain head rest
- Neck flexed by 15 degrees and tilted to opposite side by 15- 20 degrees
- Confirm with an image intensifier
- Clean and drape
- Prepare thigh

Techniques and incision



- Routes: 1. Trans nasal – Direct endonasal
Anterior mucosal incision
- 2. Sub labial



Introduction of speculum



- Septum broken and Hardy's speculum introduced
- Perpendicular plate seen which is removed to enter sphenoid sinus

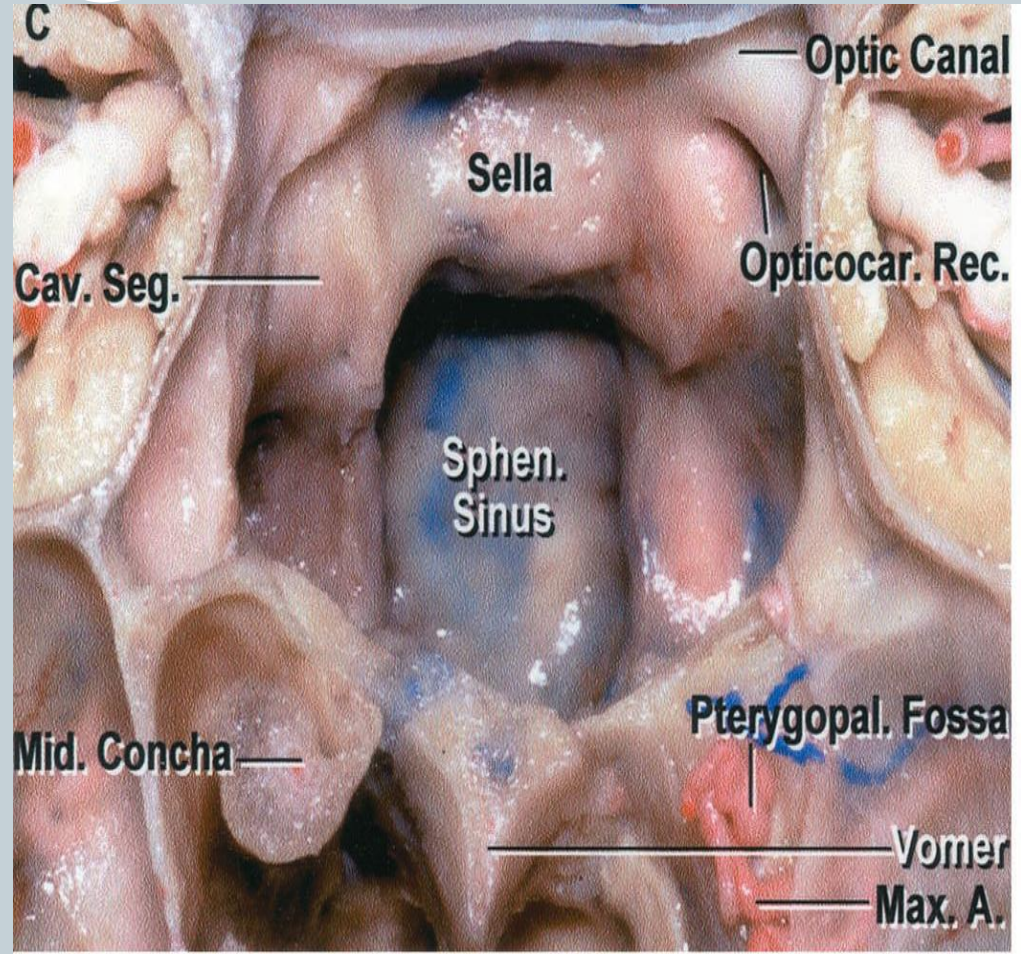


Generally speaking, the suction tip is usually brought into the speculum with the left hand (in right-handed surgeons) from approximately the 10 'o'clock position, with the other instruments entering the speculum at approximately the 5'o'clock position.

In the sinus



- Mucosa stripped off
- Position confirmed by an image intensifier
- Floor of sella then opened

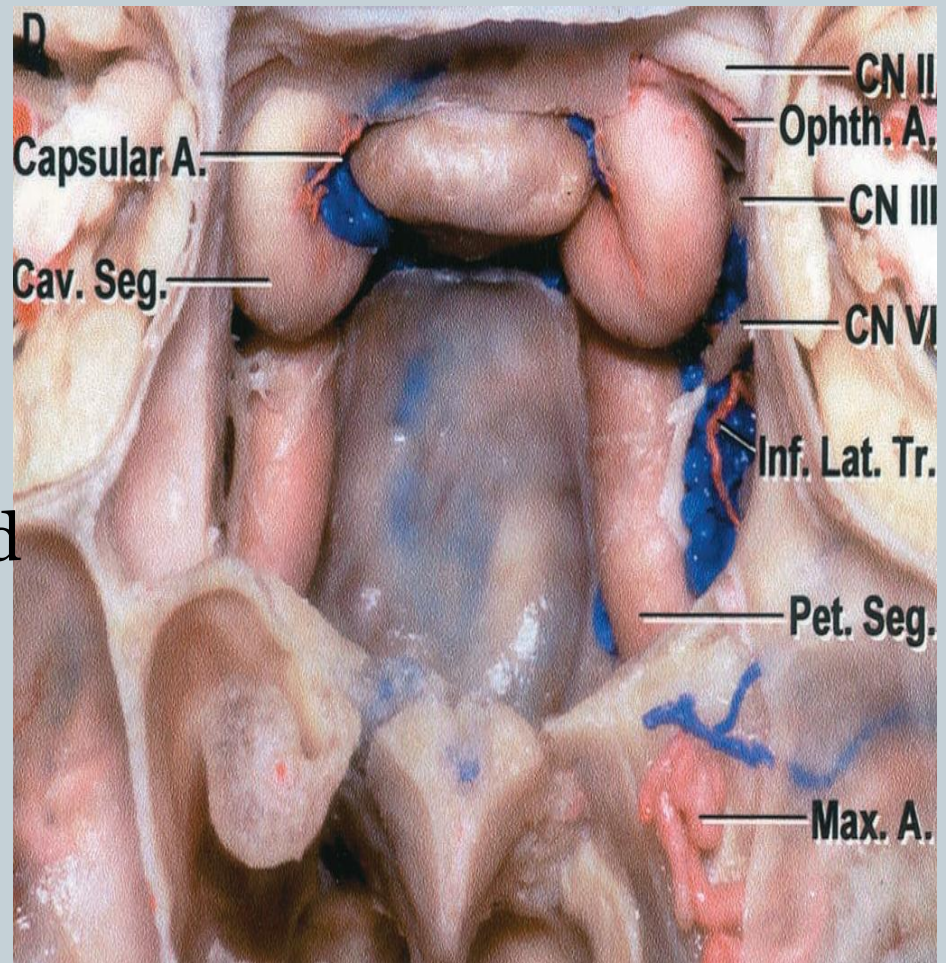




An inspection of the dura of the sella reveals in almost every case a small, centrally positioned arterial vessel emanating from the dura.

When opening the dura, it is probably better to open the middle and inferior segments of the dura first so as not to disturb a possible deep anterior arachnoid recess.

- Dura opened in a cruciate manner.
- Tumor decompression from posterior, lateral margins and finally anteriorly.





When removing a microadenoma that is visible either on the surface or through a much-distended layer of normal pituitary, look for a cleavage plane between the microadenoma and the residual normal anterior pituitary.

This plane can easily be established with a no. 11-blade knife and subsequently can be developed with loop curettes and other dissectors, working in an alternating manner from opposite sides of the microadenoma.



Prefer the use of loop curettes to ring curettes because of the absence of any sharp edges in loop curettes that could prove injurious to the surrounding structures, such as the cavernous sinus and the overlying arachnoid.



When the microadenoma is not on the surface, look for any change in the appearance of the overlying anterior pituitary such as discoloration or attenuated texture, before making the incision along the surface between the changed and the more normal-appearing anterior pituitary.



At times, it is necessary to remove a small portion of the normal anterior pituitary to gain sufficient exposure for the complete removal of a microadenoma.



Recognition of the arachnoid, which is usually covered by a thin layer of residual normal anterior pituitary, is a critical point in the operation.

Failure to identify the arachnoid and distinguish it from the surrounding suprasellar tumor can lead to penetration into the subarachnoid space, with the possibility of injuring the subarachnoid neurovascular structures.



CLOSURE

If definitive evidence of CSF escape during the operation exists, the inverted arachnoid and the defect in it should be covered with an autologous fascia graft removed from either the fascia lata or the abdominal fascia. The fascia is covered with a layer of autologous fat.



Autologous fibrin glue can be used to hold the fat graft in place and seal all of the gaps around it.

If evidence of significant CSF escape during the operation is found, especially during an extended transsphenoidal approach, a lumbar subarachnoid drain should be placed in the patient for several days after the operation.



- In micro adenomas transverse incision may have to be made on pituitary
- Confirm completion
- Closure:-pack if CSF leak has occurred
- SLTS incision closed
- Nasal packs introduced

Neuro navigation and MRI



- Wide spread acceptance
- Navigational devices offer a more real time imaging
- Care regarding registration errors
- Obviates the need for repeated X- Rays
- Intra operative MRI for completion of surgery

Complications



- Septal perforation
- Deviated nasal septum
- Nasal blockage, crusting
- Hormonal imbalances
- CSF rhinorrhoea
- Apoplexy
- Residual tumor
- Hypoosmia
- Gingival numbness

EXTENDED TRANSPHENOIDAL APPROACH



Until recently, craniotomy was thought to be the only alternative to transsphenoidal microsurgery in patients with large and asymmetrically extending suprasellar tumor components and in patients with a significantly constricted diaphragma sellae.

Some of these pituitary tumors, however, can be reached and successfully removed using an extended transsphenoidal microsurgical approach.



After opening the anterior sella wall up to the tuberculum sellae, the posterior portion of the planum is drilled out with the use of microdrill with a diamond burr .

The intervening bone of the tuberculum sella is drilled out last.

Intracranial navigation is useful to open the dura at the midline above and below the superior circular sinus, which is then coagulated and divided, again strictly in the midline.



The remaining dura can be shrunk with bipolar coagulation.

The surgeon thus gains access to the suprasellar space along a trajectory that allows for direct, unobstructed visualization of the suprasellar tumor.

The dissection of the tumor again proceeds along the tumor arachnoid interface, with the goal always being to maintain the integrity of the arachnoid membrane.

When the procedure is completed, there is copious inversion of the arachnoid membrane into the created cranial base defect.

Endoscopic endo nasal approach



- Pioneered in 1963 by Gerard Guiot
- Advantages:
 1. Nasal part of procedure simpler
 2. Wider angle of operation
 3. More safer as all structures are visualized
 4. Less traumatic
 5. Less time consuming in experienced hands
- Disadvantages:
 1. Two dimensional image
 2. Skill and training
 3. Blood can blur vision

Pertinent sino nasal anatomy



- Opening of various sinuses
- Approach through area between middle turbinate and septum
- Posterior septal artery
- Surgical landmarks are the nasopharynx and the middle turbinate

Surgical procedure



- Endoscopes with 0, 30 and 70 degree angles
- Positioning: Torso elevated by 20 degrees
- Forehead –chin line horizontal
- Neck neutral- for sella
- Flexion for clival region
- Extension for anteriorly place lesions
- Head rotated by 20 degrees towards the surgeon

Surgical approaches



- Para septal
- Middle meatal
- Middle turbinectomy

Technique



- Endoscope inserted at an angle of 25 degrees
- Inferior margin of middle turbinate identified
- 1 to 1.5 cm sphenoidotomy performed
- Coagulation of postero lateral septal artery
- Once inside sphenoid sinus, mucosa not stripped
- Carotid and cavernous sinus protuberances identified laterally, tuberculum sella and optic protuberances rostrally
- Sella opened
- Dura opened cruciate
- Tumor resection with currette and suction
- Packing of sella if intraoperative CSF leak

Extended approach for anteriorly placed lesions



- Head 15 degree extension
- Procedure carried out similarly for pituitary
- Further rostral removal of posterior ethmoids
- This itself devascularizes most of the tumors
- Bony removal by drill or rongeurs
- Tumor de-bulking from centre to posterior
- Main problem is CSF leak
- Adequate packing necessary

Complications



- Hypothalamic damage
- CSF leak
- Meningitis
- Vascular injury
- Visual loss
- Hormonal
- Septal perforation
- Mucosal atrophy
- Nasal crusting
- Mucoceles

Trans ethmoidal approach



- Indications same as that for trans sphenoidal approach
- Advantages:
 1. Shortest route to sella
 2. View not restricted by speculum
 3. No need for image intensifier
 4. Reoperations for recurrences easy
- Disadvantages:
 1. Scar
 2. Lateral to medial approach- midline can be missed



- Head flexed by 30 degrees and turned to right by 15 degrees
- Both nostrils are packed
- Eyes protected
- Curvilinear incision medial to the eye 1- 1.5cm
- Skin and orbicularis retracted
- Periosteum separated and bone exposed
- Laminae papyracea opened up preserving the lacrimal duct
- Operating microscope
- Ethmoid sinus mucosa stripped
- Identify the keel of sphenoid sinus wall
- Midline verified by passing long forceps through nostril



- Further opening of sellar floor and tumor removal and closure carried out similar to trans sphenoidal approach
- Complications
 1. Lacrimal duct avulsion
 2. Do not enter anterior cranial fossa
 3. Care while removing the mucosa from superior aspect of ethmoid sinus
 4. Stay in midline
 5. Rest of the complications similar to TNTS

INDICATIONS FOR TRANSCRANIAL APPROACH



Dumbbell-shaped adenoma with Severe Constriction at the Diaphragma Sellae:

The indication most often cited for a transcranial approach is the dumbbell-shaped pituitary adenoma with a “narrow” waist. This narrowing is created by a diaphragma sellae that is very thick and by an opening for the pituitary stalk that is very small.

Parasellar Extension



- Pituitary adenomas often invade one or both cavernous sinuses.
- This invasion may be more likely attributed to the porosity of the medial wall of the cavernous sinus in a particular patient than to specific cellular characteristics.
- For most patients who have nonsecretory adenomas with cavernous sinus invasion, tumor removal from the medial compartment of the cavernous sinus is sufficient for cytoreduction and neurovascular decompression in preparation for radiotherapy or radiosurgery.
- A transcranial approach to the cavernous sinus is occasionally indicated to restore oculomotor function.



Inaccessible Suprasellar Extension

If the suprasellar component of the adenoma is judged to be inaccessible because the sella has not enlarged, the pituitary gland may be vulnerable in a transsphenoidal approach.

In this case, the suprasellar component spills onto the planum sphenoidale , or the suprasellar component is giant and encases the optic nerves or intracranial arteries.



Fibrous Pituitary Adenoma with Large Suprasellar Extension:

Approximately 70% of pituitary adenomas with a homogeneously isointense (rather than hyperintense) signal on T2-weighted magnetic resonance images are predicted to be firm and fibrotic.



Active Sinus Infection

Sinus infection serves as an indication for use of a transcranial approach only when the infection is severe and delay to surgery may pose a threat to the patient that would result in acute deterioration of neurological function.



Coexistence of Pituitary Adenoma and Adjacent Aneurysm

Pituitary adenomas are reported in association with aneurysms at twice the frequency expected on the basis of their independent occurrence rates.

The transcranial approach is considered, along with the alternatives of surveillance of either lesion, a staged procedure, and non surgical remedies that include coiling for the aneurysm and radiotherapy/radiosurgery for the adenoma.



Ectatic Intrasellar “Kissing” Carotid Arteries

The distance separating the medial margin of the ICA from the lateral surface of the pituitary gland usually varies from 1 to 3 mm .

Dolichoectatic ICAs, especially in patients with acromegaly, may deviate medially and at times be found to meet or “kiss” within the sella . In this circumstance, the transsphenoidal approach can be hazardous.

Sub frontal approach



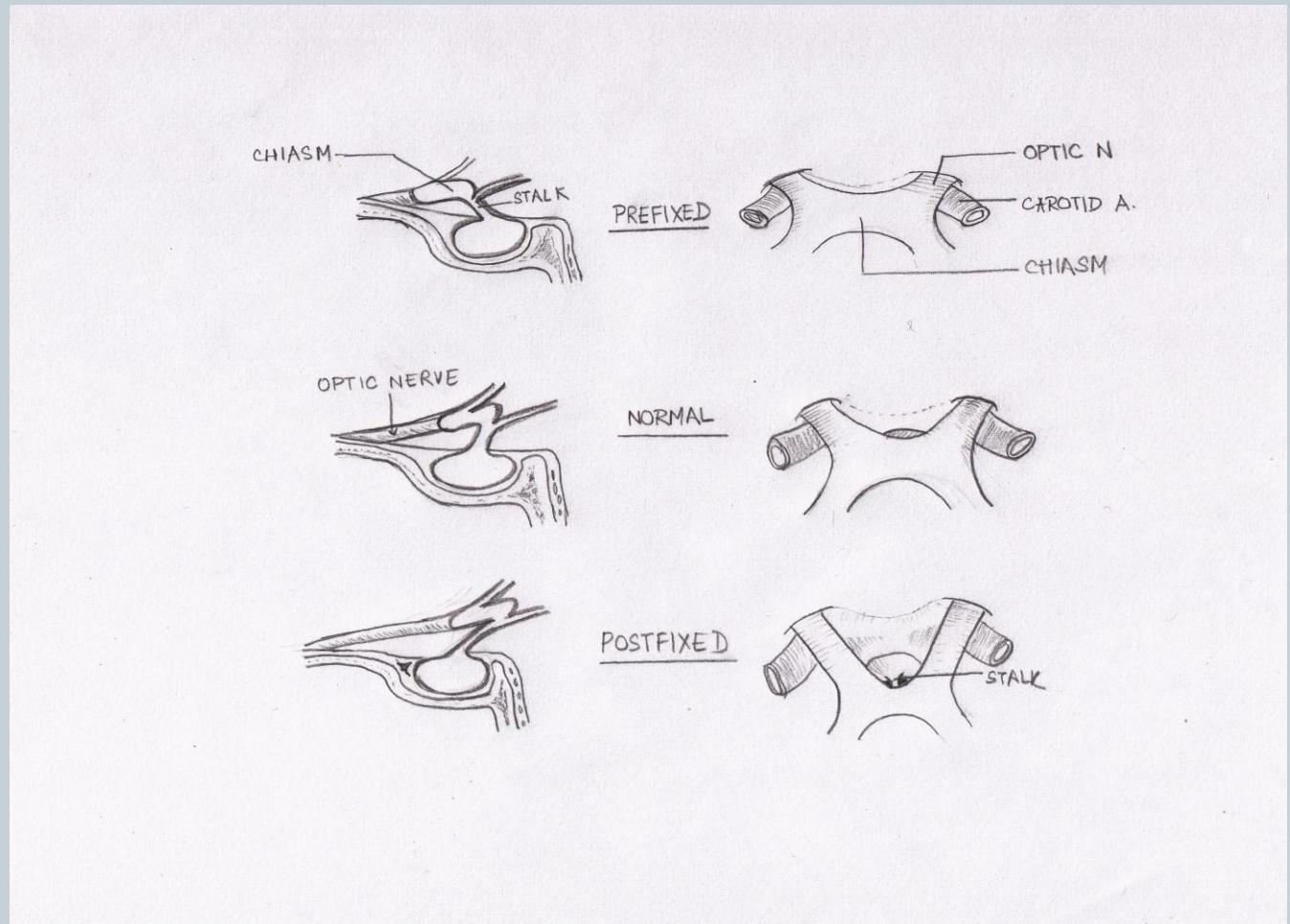
- One of the most widely used approaches
- Advantages:
 1. Direct view of all vital structures
 2. Excellent anatomical orientation
 3. Multiple corridors for removal of extensions
 4. Intra sellar extension accessible through the inter optic corridor
- Disadvantages:
 1. Frontal sinuses opened up
 2. Anosmia
 3. Frontal lobe retraction
 4. Difficulty in a prefixed chiasm

Pertinent Supra sellar anatomy



- Optic canal
- Intracranial optic nerve 15 mm diameter
- Arteries – ICA giving rise to ophthalmic, posterior communicating and the anteriorly choroidal arteries
- ICA bifurcation

- Chiasm can be : Normal
Pre fixed
Post fixed



Cisternal anatomy



- Carotid cistern
- Chiasmatic cistern
- Lamina terminalis cistern
- Inter peduncular cistern

Positioning



- Trunk elevated by 20 degrees
- Head extended by 45 degrees, neutral position
- Horse shoe or three point fixation

Incision



- Bi coronal skin incision or frontal skin flap or pterional skin incision
- Frontal craniotomy performed either unilateral or bilateral



- If bilateral, sagittal sinus is ligated and cut
- Craniotomy flush with superior orbital margin
- Pack frontal sinus



- Frontal lobe retracted
- Olfactory tract dissected from the chiasm and protected
- Often necessary to open the Sylvian fissure

Various corridors



- Inter optic corridor: for long optic nerves with tumor lying between the nerves
- Lamina terminalis corridor: Posterior extension of tumor, prefixed chiasm
- Push the tumor through lamina terminalis and remove via inter optic corridor



- Drilling of planum sphenoidale if prefixed chiasm
- In case of craniopharyngioma and meningioma, optic chiasm elevated
- Tuberculum sellae tumor pushes the nerves outward and backward
- Tumors arising from the anterior clinoid process compress the ipsilateral optic nerve before going to opposite side
- Tumors may engulf the nerve and vessels requiring careful dissection
- Preserve all perforating branches
- Identify pituitary stalk
- Plain of cleavage for hypothalamus.
- No pulling of tumor
- Meticulous closure



- **Complications:**

1. Skin necrosis, facial paresis, orbital swelling
2. Rhinorrhoea, meningitis
3. Pneumocephalus
4. Anosmia
5. Frontal contusion
6. Perforator avulsions
7. Vasospasm
8. Direct neural injury
9. Pituitary deficiency

Orbitozygomatic approach



Advantages

- Enhanced exposure of the area of interest
- Unobstructed, short and direct view
- Brain retraction minimized
- Possible to remove tumors extending to optic canal, orbit, temporal fossa, prepontine/interpeduncular cistern
- Early interruption of blood supply through sphenoid ridge minimizing blood loss
- Eliminates need for orbital reconstruction
- Allows access through multiple routes

Essential steps



- Skin incision preserving temporalis fascia and pericranium
- Transfascial management of temporalis fascia to preserve frontalis branch of facial nerve
- Tailored zygomatic osteotomy
- Rotational removal of temporalis muscle out of temporalis fossa
- Pterional craniotomy

Essential steps



- Tailored supraorbital osteotomy
- Tailored orbital osteotomy
- Tailored extradural removal of portions of greater and lesser wings of sphenoid exposing superior orbital fissure
- Low and wide dural opening
- Sylvian fissure dissection
- Optional extradural of anterior clinoid or intradural removal of posterior clinoid

.FTOZ video



Visit -

<http://aiimsnets.org/SkullBaseApproaches.asp#>

Trans Sylvian approach



- Supine on horse shoe or three pin fixation
- Head elevated by 20 degrees
- Head turned to opposite side by 15 degrees and extended by another 20 degrees so that malar prominence is the highest
- Side of procedure by lateral extension of tumor and pre operative deficits



- Pterional skin flap
- Care taken to preserve the facial nerve branches and superficial temporal artery
- Standard bone flap raised
- Sphenoid ridge drilled out
- Dura opened in curvilinear fashion
- Further technique proceeds either through trans Sylvian or sub frontal route
- Arachnoid opened in Sylvian fissure to let out the CSF and frontal lobe retracted
- Carotid cistern opened and major vessels identified



- Tumor will be seen by this time
- Various corridors used:
Inter optic, optico- carotid, carotico tentorial, lamina terminalis, between the carotid bifurcation
- In cases of cystic tumors, decompressed, capsule coagulated
- When chiasm is pre fixed, lamina terminalis or between carotid and chiasm
- Perforators separated carefully
- Drilling of tuberculum sellae for view of sella
- Hemostasis and meticulous closure



- **Advantages of addition of orbitozygomatic extension**
 1. Short and direct surgical access to deep seated lesions
 2. Offers low basal approach to the anterior and middle fossae with minimal retraction of frontal and temporal lobes
 3. Allows access through multiple routes
 4. Larger exposure for specially posteriorly located lesions
 5. Early interception of tumors blood vessels.



- **Complications:**

1. Facial paresis, skin flap necrosis
2. Opening of frontal sinus
3. Anosmia
4. Lobar retraction
5. Perforator injury
6. Pituitary damage
7. Neural injury

Anterior Inter hemispheric approach



- For supra sellar lesions lying predominantly above the chiasm
- Head fixed on three pin fixation or horse shoe head rest
- Head extended by 15 to 20 degrees and tilted to right for the frontal lobe to fall
- Approach through a bicoronal skin flap and a parasagittal craniotomy
- Dissection of anterior inter hemispheric fissure done as low as possible to reach the pathology
- The paired ICA's are identified as they emerge out.